

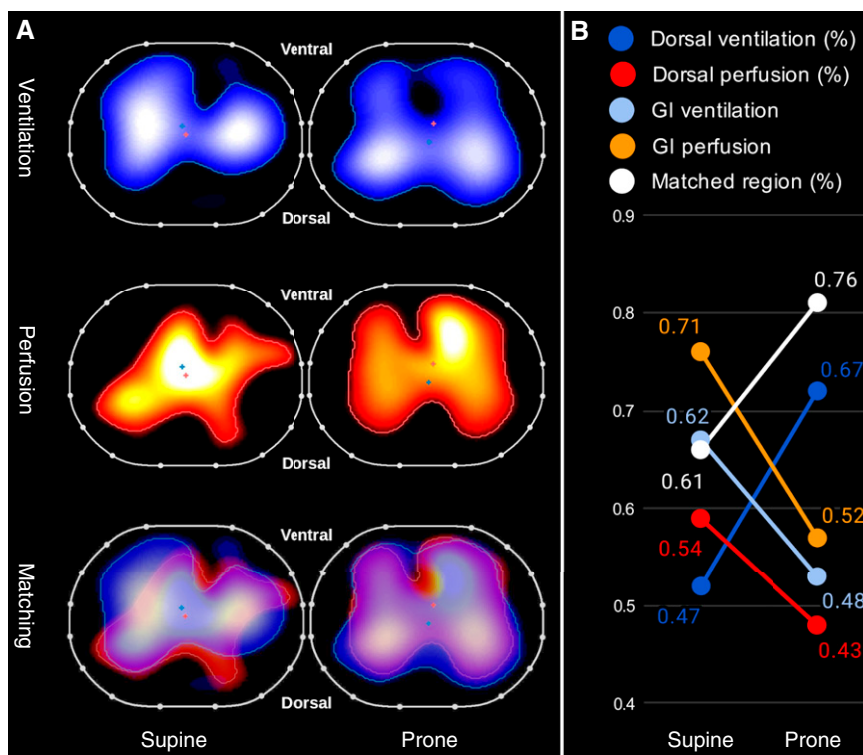
# IMAGES IN PULMONARY, CRITICAL CARE, SLEEP MEDICINE AND THE SCIENCES

## Prone Position and Lung Ventilation and Perfusion Matching in Acute Respiratory Failure due to COVID-19

Francesco Zarantonello<sup>1</sup>, Giulio Andreatta<sup>2</sup>, Nicolò Sella<sup>2</sup>, and Paolo Navalesi<sup>1,2</sup>

<sup>1</sup>Anesthesia and Intensive Care Unit, University Hospital of Padua, and <sup>2</sup>Department of Medicine, University of Padua, Padua, Italy

ORCID IDs: 0000-0002-5217-9669 (F.Z.); 0000-0003-0648-1565 (G.A.); 0000-0001-9338-4995 (N.S.); 0000-0002-3733-3453 (P.N.).



**Figure 1.** (A) Transverse thoracic electrical impedance tomography images illustrating (from top to bottom) the distribution of tidal ventilation (blue–white gradient area), lung perfusion (red–yellow gradient area), and the two overlaid. Images were acquired with the patient in a supine position and 1 hour after prone positioning. (B) Plot illustrating the variations in the ventilation and perfusion distribution, as recorded with electrical impedance tomography. GI = global inhomogeneity index.

A 70-year-old man (body mass index = 29 kg/m<sup>2</sup>) was admitted for acute respiratory failure consequent to severe acute respiratory syndrome coronavirus 2 (SARS-CoV-2) infection. He had no disease in his past medical history and received no medication. He was intubated and mechanically ventilated with a V<sub>T</sub> of 6 ml/kg of ideal body weight, a respiratory rate of 25 breaths/min, positive end-expiratory pressure of 12 cm H<sub>2</sub>O, and an F<sub>I</sub>O<sub>2</sub> of 0.6. Because of severe hypoxemia (Pa<sub>O<sub>2</sub></sub>/F<sub>I</sub>O<sub>2</sub> = 118 mm Hg), the patient underwent prone positioning, which resulted in Pa<sub>O<sub>2</sub></sub>/F<sub>I</sub>O<sub>2</sub> improvement (263 mm Hg) after 1 hour (1). As previously attempted (2), we recorded images of lung ventilation and perfusion at the fifth intercostal space by using electrical impedance tomography (Pulmo Vista 500; Dräger Medical), with the patient supine and after 1 hour of pronation, maintaining the ventilator settings unchanged. Both ventilation and perfusion changed from the supine to the prone position (Figure 1). Ventilation increased in the dorsal half of the thorax (+20%), whereas perfusion decreased (–11%) in the same area, moving toward the

This article is open access and distributed under the terms of the Creative Commons Attribution Non-Commercial No Derivatives License 4.0 (<http://creativecommons.org/licenses/by-nc-nd/4.0/>). For commercial usage and reprints, please contact Diane Gern ([dgern@thoracic.org](mailto:dgern@thoracic.org)).

Author Contributions: F.Z. was involved in the case, conceptualized the management, acquired and analyzed the data, and wrote the manuscript. G.A. was involved in the case, conceptualized the management, and wrote the manuscript. N.S. conceptualized the management and edited the manuscript. P.N. conceptualized the management, edited the manuscript, and supervised the work.

Am J Respir Crit Care Med Vol 202, Iss 2, pp 278–279, Jul 15, 2020

Copyright © 2020 by the American Thoracic Society

Originally Published in Press as DOI: 10.1164/rccm.202003-0775IM on May 21, 2020

Internet address: [www.atsjournals.org](http://www.atsjournals.org)

ventral areas. However, the global inhomogeneity index (3) decreased for both ventilation and perfusion, overall increasing ventilation and perfusion matching in the lung, which may help explain the observed improvement in oxygenation with prone positioning in patients with acute respiratory failure secondary to SARS-CoV-2. ■

**Author disclosures** are available with the text of this article at [www.atsjournals.org](http://www.atsjournals.org).

---

## References

1. Guérin C, Reignier J, Richard J-C, Beuret P, Gacouin A, Boulain T, *et al.*; PROSEVA Study Group. Prone positioning in severe acute respiratory distress syndrome. *N Engl J Med* 2013;368: 2159–2168.
2. Tingay DG, Waldmann AD, Frerichs I, Ranganathan S, Adler A. Electrical impedance tomography can identify ventilation and perfusion defects: a neonatal case. *Am J Respir Crit Care Med* 2019;199:384–386.
3. Zhao Z, Möller K, Steinmann D, Frerichs I, Guttman J. Evaluation of an electrical impedance tomography-based global inhomogeneity index for pulmonary ventilation distribution. *Intensive Care Med* 2009;35:1900–1906.