

## **Radiology-pathology Correlation in Recovered COVID-19, Demonstrating Organizing Pneumonia**

Brian P Pogatchnik, MD\*,<sup>1</sup> Kai E Swenson, MD\*,<sup>2</sup> Husham Sharifi, MD,<sup>2</sup> Harmeet Bedi, MD<sup>2</sup>  
Gerald J Berry, MD,<sup>3</sup> H. Henry Guo, MD PhD<sup>1</sup>

\*These authors contributed equally in work.

<sup>1</sup>Department of Radiology, Stanford University School of Medicine, Stanford, CA, USA

<sup>2</sup>Division of Pulmonary, Allergy and Critical Care Medicine, Department of Medicine, Stanford  
University School of Medicine, Stanford, CA, USA

<sup>3</sup>Department of Pathology, Stanford University School of Medicine, Stanford, CA, USA

Corresponding Author: H. Henry Guo, MD PhD,

Stanford School of Medicine

300 Pasteur Drive, S078A

Stanford, CA 94305

Email: [henryguo@stanford.edu](mailto:henryguo@stanford.edu)

Contributions:

Conception and design: BP, KS, HG; Analysis and interpretation: BP, KS, HS, HB, GB, HG; Drafting  
the manuscript for important intellectual content: BS, KS, HS, HB, GB, HG

Funding: No funding was provided for this study.

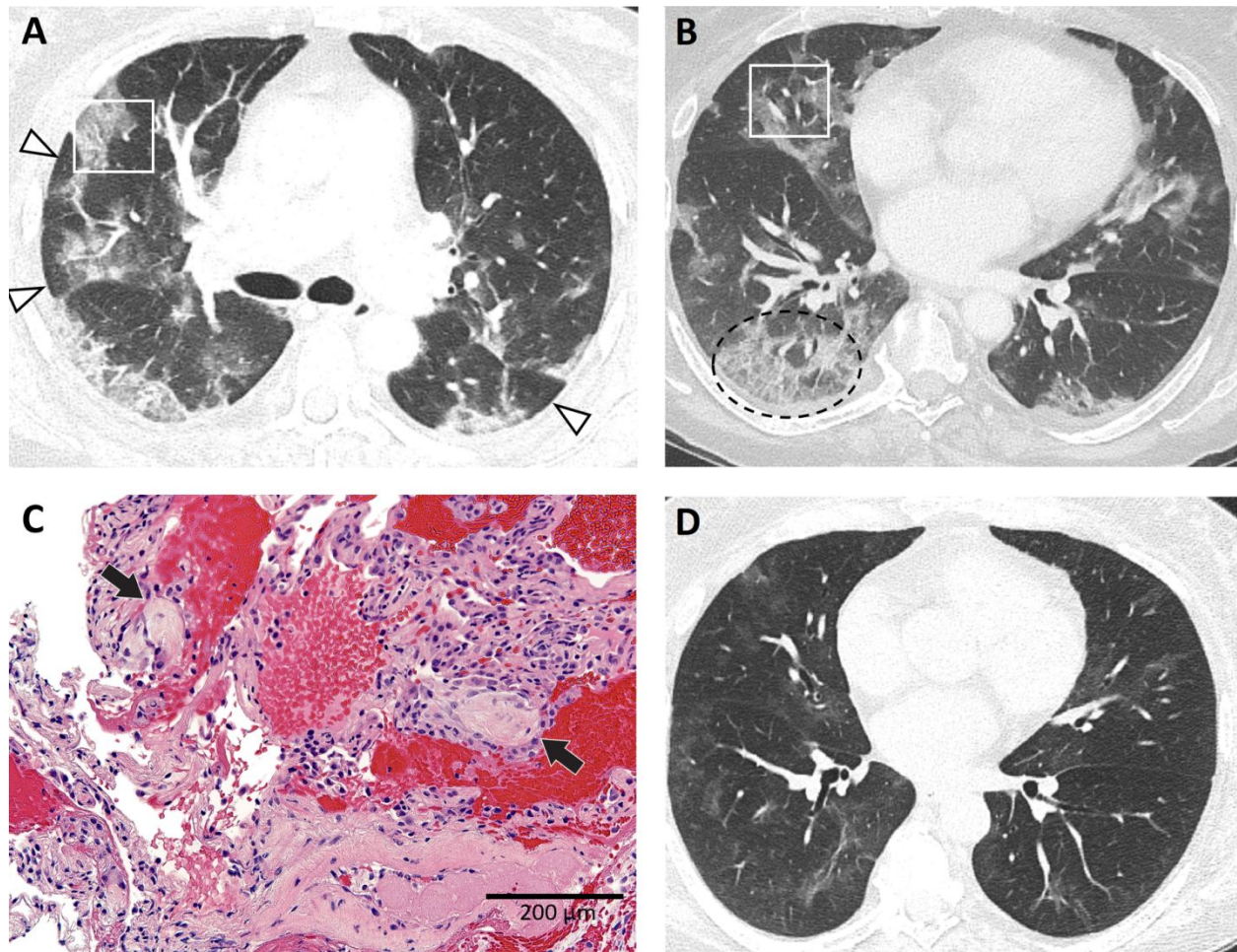
Subject Category: 10.14 Pneumonia: Viral Infections < MICROBIOLOGY AND PULMONARY  
INFECTIONS

This article is open access and distributed under the terms of the Creative Commons Attribution  
Non-Commercial No Derivatives License 4.0 ([http://creativecommons.org/licenses/by-nc-  
nd/4.0/](http://creativecommons.org/licenses/by-nc-nd/4.0/)). For commercial usage and reprints please contact Diane Gern ([dgern@thoracic.org](mailto:dgern@thoracic.org)).

**Case:**

The few pathological analyses of COVID-19 pneumonia to date, mostly from autopsy studies, report diffuse alveolar damage (DAD) or acute fibrinous and organizing pneumonia (AFOP) (1-3). In contrast, CT imaging from numerous COVID-19 patients include features more consistent with organizing pneumonia (OP) (4, 5). A previously healthy 61-year-old woman presented with 3 weeks of dyspnea, cough, and fevers; nasopharyngeal RT-PCR for SARS-CoV-2 and common respiratory pathogens was negative. CT on day 3 of admission demonstrated peripheral and basilar patchy opacities with perilobular sparing, consistent with an OP pattern (Fig. 1a,b). The patient had no signs or symptoms of an underlying rheumatologic condition and took no medications. Two days later, transbronchial biopsies throughout the right lung peripherally revealed scattered fibromyxoid plugs within distal airspaces indicative of a histologic OP pattern (Fig. 1c). RT-PCR for SARS-CoV-2 returned positive by bronchoalveolar lavage (BAL); other BAL cultures were unremarkable. The patient was started on remdesivir and made a full clinical recovery. CT 26 days later showed minimal residual opacities (Fig. 1d). OP findings in this case may stem from tissue sampling later in a self-limited course of mild-moderate COVID-19. Confirmed radiographically and histologically, organizing pneumonia as an active and sometimes aberrant lung repair process may represent the evolution of COVID-19 in patients with mild-moderate disease.

**Author statement:** This is an original work and the following case has not been published elsewhere.



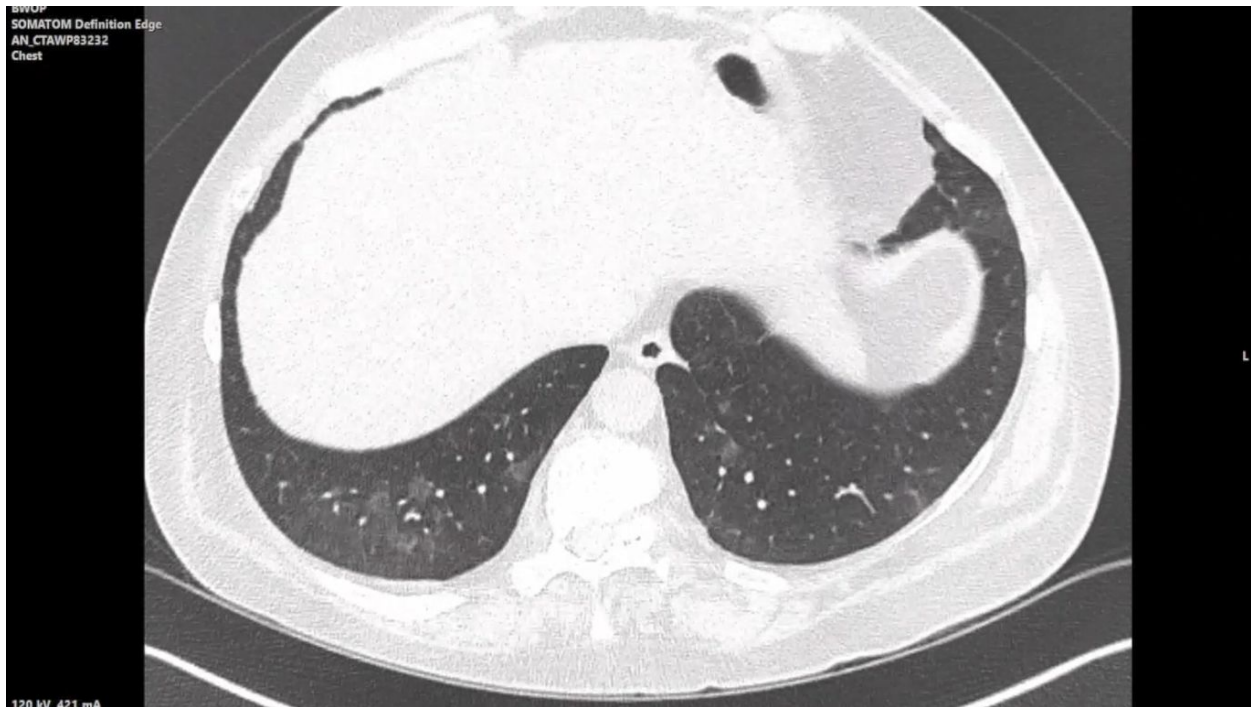
**Figure 1:** A: Axial CT image of the mid lung zones showing areas of “perilobular” distribution (open arrows) of pulmonary opacities, in a pattern consistent with organizing pneumonia. Approximate area of transbronchial biopsy in the anterior segment of the right upper lobe (white rectangle). B: Axial CT image of the lower lung zones showing patchy ground-glass opacities distributed peripherally in the lungs and “crazy paving” in the posterior-basal right lower lobe (hashed circle). Approximate area of biopsy in the right middle lobe (white rectangle). C: High power magnification of alveolated lung containing scattered fibromyxoid plugs of granulation tissue and sparse interstitial mononuclear infiltrates, indicating organizing pneumonia. (Hematoxylin and Eosin, x200). D: Follow-up CT performed 26

days later with axial image at the same location as panel B, near the level of the inferior pulmonary veins, demonstrate nearly resolved pulmonary opacities. Video clips through the entirety of both CT scans are available below and in supplemental materials S1.

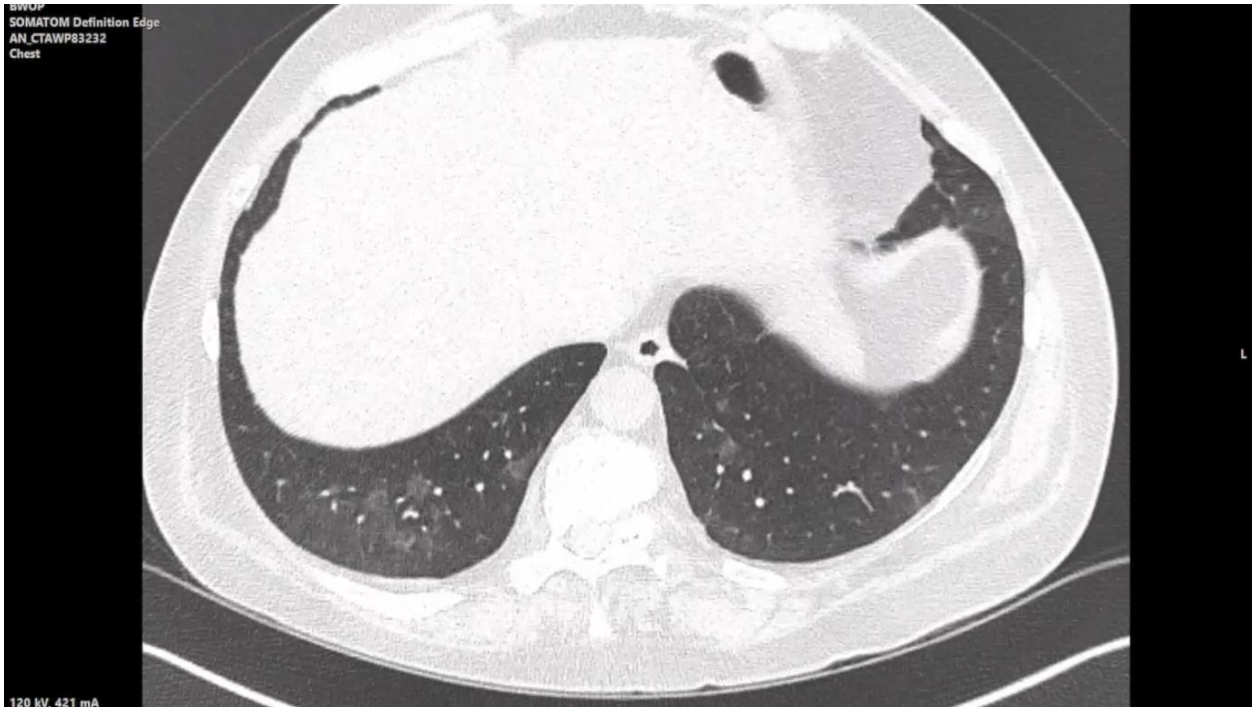
Video-Presentation CT: Axial CT images through the chest without contrast of the patient on hospital day 3.

**References:**

1. Xu, Zhe, Lei Shi, Yijin Wang, Jiyuan Zhang, Lei Huang, Chao Zhang, Shuhong Liu, et al. "Pathological Findings of COVID-19 Associated with Acute Respiratory Distress Syndrome." *The Lancet Respiratory Medicine* 8, no. 4 (2020): 420–22. [https://doi.org/10.1016/s2213-2600\(20\)30076-x](https://doi.org/10.1016/s2213-2600(20)30076-x).
2. Copin, Marie-Christine, Erika Parmentier, Thibault Duburcq, Julien Poissy, and Daniel Mathieu. "Time to Consider Histologic Pattern of Lung Injury to Treat Critically Ill Patients with COVID-19 Infection." *Intensive Care Medicine*, 2020. <https://doi.org/10.1007/s00134-020-06057-8>.
3. Tian, Sufang, Yong Xiong, Huan Liu, Li Niu, Jianchun Guo, Meiyan Liao, and Shu-Yuan Xiao. "Pathological Study of the 2019 Novel Coronavirus Disease (COVID-19) through Postmortem Core Biopsies." *Modern Pathology*, 2020. <https://doi.org/10.1038/s41379-020-0536-x>.
4. Song, Fengxiang, Nannan Shi, Fei Shan, Zhiyong Zhang, Jie Shen, Hongzhou Lu, Yun Ling, Yebin Jiang, and Yuxin Shi. "Emerging 2019 Novel Coronavirus (2019-NCoV) Pneumonia." *Radiology* 295, no. 1 (2020): 210–17. <https://doi.org/10.1148/radiol.2020200274>.
5. Kanne, Jeffrey P., Brent P. Little, Jonathan H. Chung, Brett M. Elicker, and Loren H. Ketani. "Essentials for Radiologists on COVID-19: An Update—Radiology Scientific Expert Panel." *Radiology*, 2020, 200527. <https://doi.org/10.1148/radiol.2020200527>.



Presentation CT Video Still



“Follow Up CT” Video Still