

Letters

OBSERVATION

Sudden and Complete Olfactory Loss Function as a Possible Symptom of COVID-19

The novel coronavirus disease 2019 (COVID-19) caused by severe acute respiratory syndrome coronavirus 2 (SARS-CoV-2) infects the human respiratory epithelial cells. The clinical features of patients infected with SARS-CoV-2 included lower respiratory tract infection with fever, dry cough, and dyspnea.¹ In contrast, upper respiratory tract symptoms are less common, suggesting that the cells targeted by the virus could be located in the lower respiratory tract.¹

Herein we present a case where the main symptom expressed by the patient infected by SARS-CoV-2 was the sudden and complete loss of the olfactory function without nasal obstruction.

Report of a Case | A woman in her 40s presented with an acute loss of the olfactory function without nasal obstruction. There was no dysgeusia because the patient reported no changes in salty, sweet, sour, and bitter. A few days before presentation, she also experienced a dry cough associated with cephalalgia and myalgia. She had no fever or rhinorrhea. The otoscopic and anterior rhinoscopic examination results (without endoscopic examination) were normal.

The ability to detect and identify odorants was estimated using 5 odorants commonly used to test human olfaction: phenyl-ethyl-alcohol (flower rose), cyclotene (caramel), isovaleric acid (goat cheese), undecalactone (fruits), and skatole (manure). The task was to detect and try to identify each odorant. None of these odorants were identified or detected by the patient.

The patient underwent a computed tomographic scan of the nasal cavity (**Figure 1**) that showed bilateral inflammatory obstruction of the olfactory clefts that was confirmed on magnetic resonance imaging (MRI) of the nasal cavity (**Figure 2**). There were no anomalies of the olfactory bulbs and tracts. Because her husband was also suspected to be infected by SARS-CoV-2, the patient underwent real-time polymerase chain reaction (RT-PCR) for SARS-CoV-2, which yielded positive results.

Discussion | Upper respiratory tract infection is one of the most commonly identified causes of olfactory loss, accounting for 22% to 36% of cases.² Herein, we describe a patient with COVID-19 who presented with bilateral obstructive inflammation of olfactory clefts on imaging, which severely impaired the olfactory function by preventing odorant molecules from reaching the olfactory epithelium.

The origin of this obstruction remains unknown and has been reported in patients following a severe nasopharyngeal infection.³ However, in this patient no nasal obstruction or rhinorrhea was noticed. Trotier et al³ have reported persistence

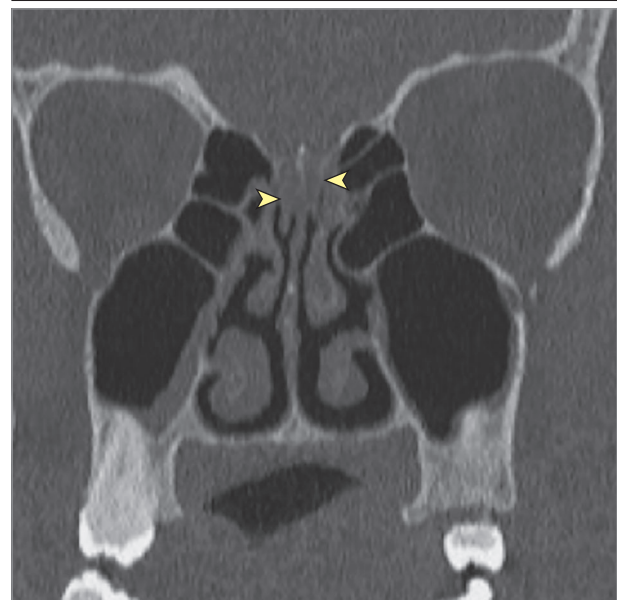of the symptoms despite inhaled corticosteroids or oral corticoid treatments associated with antibiotics. In addition, corticosteroids should be avoided in patients infected by SARS-CoV-2.

Most coronaviruses share a similar structure and infection pathway; thus, one can expect the similar infection mechanisms for SARS-CoV-2.⁴ Coronaviruses could invade the brain via the cribriform plate close to the olfactory bulb and the olfactory epithelium. We could expect some structural changes in the olfactory bulb that were not observed in this case. However, it is important to assess the volume of the olfactory bulb that might be, at this stage, too subtle to be detected on MRI results. Moreover, Yao et al⁵ have reported that the volume of the olfactory bulb is decreased in patients with postinfectious olfactory loss and is inversely related to the duration of olfactory loss.

Recently Liggett et al⁶ described an expression of the olfactory receptor family on central cortical neurons, vascular smooth muscle, and upper and lower airway epithelium. Because SARS-CoV-2 infects the human respiratory epithelial cells through an impairment of the angiotensin-converting enzyme 2 receptor, we believe that this olfactory receptor family could also be selectively impaired.¹

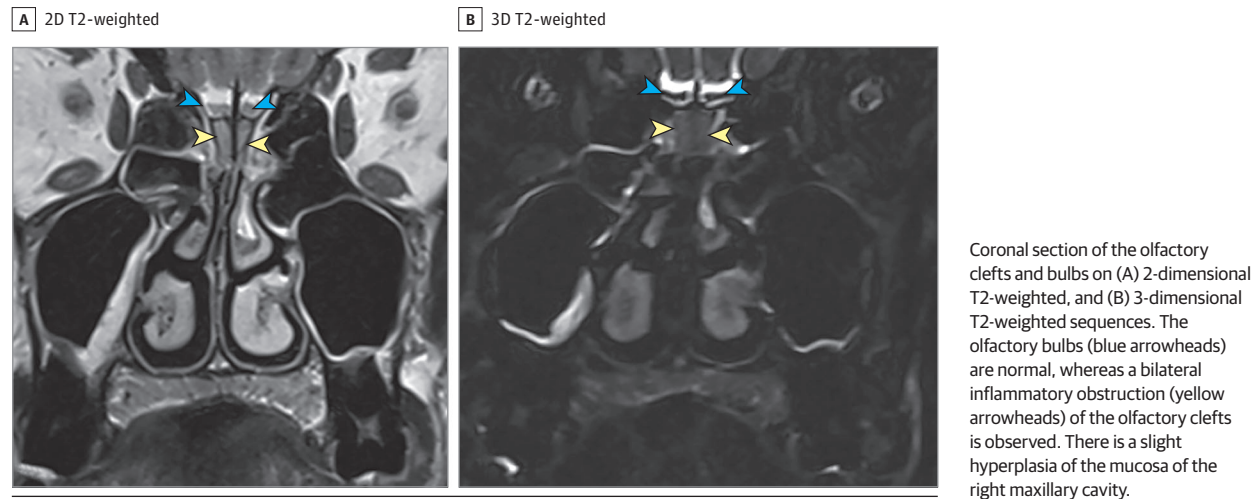
To our knowledge, this is the first report of a patient with COVID-19 presenting essentially with an olfactory function loss. As reported by the French Society of ENT (<https://www.snorl.org/category-acces-libre/alerte-anosmie-covid-19-20-mars-2020/>), we believe that the association of a sudden and

Figure 1. Nasal Cavity Computed Tomographic Image of Coronal Section



Bilateral obstruction of the olfactory cleft (yellow arrowheads) without obstruction in the rest of the nasal cavities.

Figure 2. Magnetic Resonance Images



complete olfactory function loss, without nasal obstruction in a patient with other symptoms, such as cough or fever, should alert the clinician to suspect SARS-CoV-2 infection.

Michael Eliezer, MD
Charlotte Hautefort, MD
Anne-Laure Hamel, MD
Benjamin Verillaud, MD
Philippe Herman, MD, PhD
Emmanuel Houdart, MD, PhD
Corinne Eloit, MD

Author Affiliations: Department of Neuroradiology, Lariboisière University Hospital, Paris, France (Eliezer, Houdart); Department of Head and Neck Surgery, Lariboisière University Hospital, Paris, France (Hautefort, Hamel, Verillaud, Herman, Eloit).

Corresponding Author: Michael Eliezer, MD, Neuroradiology Unit, Lariboisière University Hospital, 75010 Paris, France (michael.eliezer@aphp.fr).

Published Online: April 8, 2020. doi:10.1001/jamaoto.2020.0832

Conflict of Interest Disclosures: None reported.

Additional Contributions: We thank the patient for granting permission to publish this information.

- Huang C, Wang Y, Li X, et al. Clinical features of patients infected with 2019 novel coronavirus in Wuhan, China. *Lancet*. 2020;395(10223):497-506. doi:10.1016/S0140-6736(20)30183-5
- Seiden AM, Duncan HJ. The diagnosis of a conductive olfactory loss. *Laryngoscope*. 2001;111(1):9-14. doi:10.1097/OO005537-200101000-00002
- Trotier D, Bensimon JL, Herman P, Tran Ba Huy P, Døving KB, Eloit C. Inflammatory obstruction of the olfactory clefts and olfactory loss in humans: a new syndrome? *Chem Senses*. 2007;32(3):285-292. doi:10.1093/chemse/bjl057
- Li YC, Bai WZ, Hashikawa T. The neuroinvasive potential of SARS-CoV-2 may play a role in the respiratory failure of COVID-19 patients [published online February 27, 2020]. *J Med Virol*. doi:10.1002/jmv.25728
- Yao L, Yi X, Pinto JM, et al. Olfactory cortex and olfactory bulb volume alterations in patients with post-infectious olfactory loss. *Brain Imaging Behav*. 2018;12(5):1355-1362. doi:10.1007/s11682-017-9807-7
- An SS, Liggett SB. Taste and smell GPCRs in the lung: evidence for a previously unrecognized widespread chemosensory system. *Cell Signal*. 2018; 41:82-88. doi:10.1016/j.celsig.2017.02.002